

Landeskrankenhaus Leoben  
Hals-, Nasen- und Ohrenabteilung  
Vorstand: Prim. Univ.-Doz. Dr. Heimo Simon  
A-8700 Leoben, Vordernberger Straße 42  
Tel. (0043/3842) 401-2341, Fax (0043/3842) 401-2353



*Steiermärkische Krankenanstalten Ges. m. b. H.*

## **Case report study**

# **FOLOWING THE INFLUENCE OF MEGAMIN (TMAZ) TO ADJUVANT THERAPIES AT MALIGNANT AND TO OTHER TYPES OF DISEASES**

**Prim dr Drazen Rudes**

**Leoben, September, 2001.**

## **My experience of therapy with Megamin**

After first contact with dr Ivkovic by phone, then personal, I have started to use Megamin as a adjuvant therapy, on my clinic Loeben, in Austria. I was convinced that this product could really help to some of my patients.

Until today, Megamin was taken by 30 patients in region of the clinic where I work, (Upper Stajerska) (Bezirk leoben) in a group of 15 heavy cases of malignoma, few cases of neurological diseases, diabetes, Down syndromes, and also with few cases with heavy neurovegetative distonia, especially along with a anorexia and loss of weight, inapetency, insomnia, and loss of work competency.

Especially, my interest was connected to the patients with a malignant diseases, mostly with carcinoma of the head and neck, primary or recidive genesis and the question, how would they respond to therapy with Megamin.

In three cases with recidive genesis of malignoma, patients who had strongly egzulcerated, crater –formed metastases in lymhonodes of the neck.. In addition of heavy pain, there were smelly (necroses) and sometimes with stronger bleeding. Surgical way of stopping the bleeding was out of question, because of high caheksy patients and compressive dressing with conventional stuff like: Spongostan, Sofratil, Betaisodona, Tabotamp, Nebacetin didn't give a good results. I simply put the Megamin powder on a sterile gauze and than on the bleeding, blooming, necrotizant metastase. Bleeding was usually stopped in one hour, next days didn't appear especially if the wound was bandage twice a day. In a period of 7 days, metastases would be decreased in size by half, smaller metastases and biologically younger, would simply disappeared. Necroses parallely regressed. As a rule, all of the patients with for egz. carcinoma of oral cavity, tonsil, tongue, upper and lower jaw, hypopharinx, larynx, metastases on the neck at unknown primary process, they all gained on weight 1-3kg in a period of two to six months taking Megamin, in spite of receiving chemotherapy at the same time. They slept better, but a pain depended of taking morphine derivates, what is logical.

In one example, a married couple, both with the same disease, a chronic leukaemia, after 4 week taking Megamin, they both came in to remission which was the longest one, significantly longer then any one before.

One patient who has a carcinoma of toile, after chemotherapy she had extreme leocopenia, almost aleucosis, which was treated with Neupogen, which reverse to extreme leucocytosis of young and immature elements of white cells. After taking Megamin, 2-nd to 4-th week the number of leukocytes stabilised, we gained better condition of the patient, gain on weight, and tumour progression in tonsil area was not found.

2 female patients with Multiple sclerosis, react to Megamin very good. One with long time dizziness, they stopped after two weeks, the other one with a help of physiotherapy, could perform any movement.

The best results were at younger patients, neurovegetative dystonia patients, with restored appetite, serological test came in to referent values. At one 13 year old patient we noticed normalisation the hormone of the growth which was suppressed for a long period of time. I must underline that a doses for adolescent was significantly reduced.

All of this cases are presented with a subjective approach, but objective parameters lead us to this conclusions. Scientific approach was not possible, because of small number of the same cases.

Lately the interest for Megamin is in increased process but also with a reasonable suspicion. After all, through my experiences with Megamin, I think that deserves our attention and that this product can be classify according to quality, to homeopathic stuff. Adjuvant therapy can help us in treating many kind of diseases, especially malignant. The problem and mistake is to prescribe Megamin as a adjuvant therapy when all other was unsuccessful. It should be started much earlier, when disease is verified.

So far my experiences with Megamin are positive. In my opinion, that Megamin should be observed with respect.

O.A.dr.Drazen Rudes

Names of the patients were deliberately not listed.

## **Description of the cases**

In this case report study author presented different cases of malignoma mostly, and a treatment with adjuvant product Megamin along with a classical way. There are also some cases of different etiology.

Here are demonstrated: One case of complete remission of the carcinoma of larynx with some figures, one case of partial remission, carcinoma of supraglotis, carcinoma of paranasal sinuses, carcinoma planocelulare of the tongue, 4 cases of carcinoma of tonsillae, 2 cases of carcinoma hipofaringis, 3 adenocarcinoma of bronchus, one case of adenocarcinoma of pancreas, adenocarcinoma of colon with a metastatic process in the liver.

Other diseases demonstrated: chronic lymphatic leukemia, diabetes mellitus, multiple sclerosis and Morbus Crohn.

At the end of the study is a conclusion and opinion of the author.



Case report study

## **Conclusion**

Until today's therapy with Megamin as an adjuvant, with our clinical observations, put this new product in a very good antioxidants. Especially good effect this product has when is given early, at the beginning of disease together with classical therapy. We gained very good results when is combined together with a chemotherapy and the radiation at the same time. There are good effects also to the older patients. There is a small effect to the adenocarcinoma for example, lungs, the digestive system.

Very good effect is noticed in the metabolic diseases and restore a good blood lab findings.

We are still in observation of Megamin and it's qualities.

HNO OA Dr. Drazen Rudes  
LKH Leoben Austria



## CASE REPORT

Loeben, Jun 2001.

Case of the complete remission of carcinoma larynx.

**Patient: L.F., male, born 1929.**

Came to our department ORL 13.3.2000.

More than 2 months with hoarseness, treated with antibiotics at home. Ulcer ventriculi and silicosis for 25 years in addition.

ORL status: larynx 3x2cm in diameter, light red, lobular structured, with some blood dressing, and tumour in a region of Morgagny ventricle of the left side of larynx. Tumour in the cavity makes breathing very difficult.

RTG of lungs: emphysema, sclerosis aortae, and silicosis. EKG: sinus rhythm 88/min, AV block Io left.

Internal: chronic weakness of the heart, increased urea values in blood, chronic dysfunction of kidneys.

Sonography of the neck: multiple to 1cm big oval lymphonodes in trigonum caroticum and through neuro vascular way of neck on the left side, more then on the right side. All nodes with hilus reflex.

CT of the neck: without certain signs of foreign body, tumour.

Video act of swallowing regular.

Echocardiography: left ventricul increased and under pressure.

RTG sinuses OB

Tm markers: SCC 1.8, TPA 80.5, Cyfra 21: 4.2, all increased.

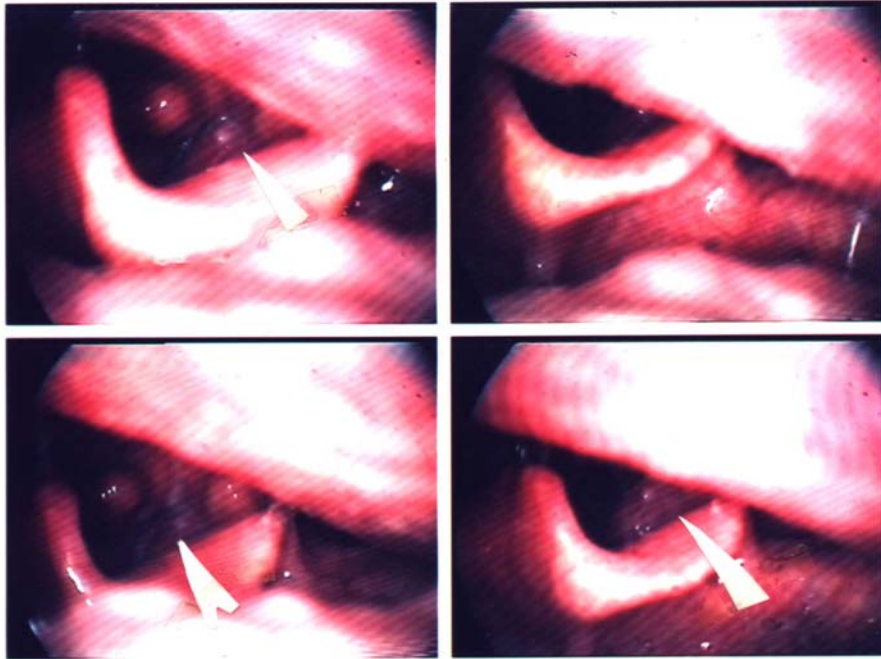
Hystological findings: **Carcinoma of larynx- G2**

With our diagnostic tests, we found carcinoma of larynx in a progression, and put indication to a total laryngectomy. Afterwards, we planed to perform chemotherapy and irradiation in 3 cycles with Cisplatin + 5 FU. But, patient refused this therapy and went home. When left, he had 89.2 kg.

He started to take alternatively Megamin in doses of 6 capsules + 2 grams of powder, daily first week, next week he took 10 capsules +3 grams of powder, then 14capsules + 4 grams of powder. He comes to control examinations permanently once a month. Through inspections we noticed some regression of the tumour. In January 2001. tumour became smaller, 4x4mm in size, left vocalis completely moveable, fonatoric function almost completely regular.

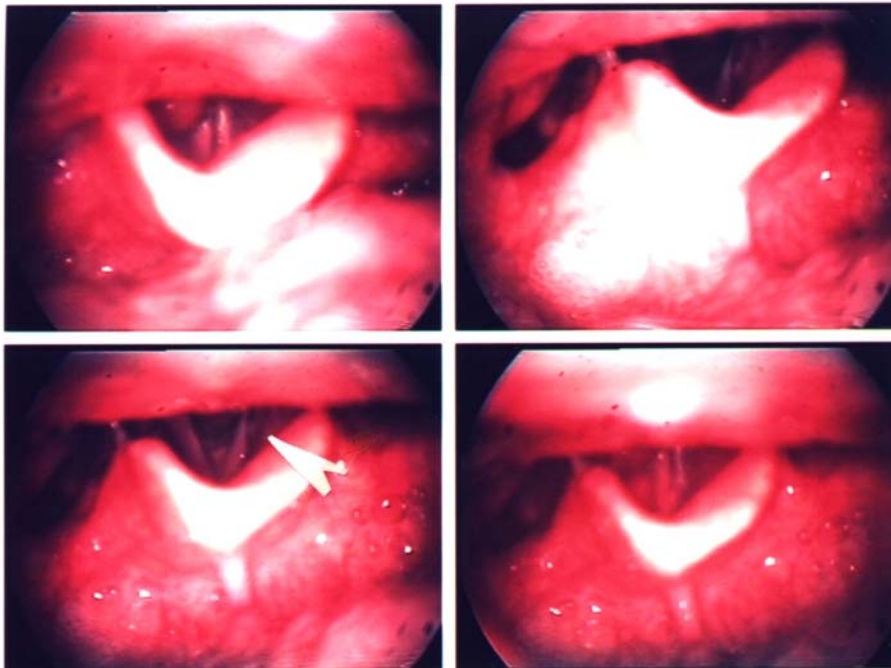
Tm markers 12.2.2001. Ca 125: 10.0; Ca 19-9 under 2.5; SCC: 0.8, TPA 98.5, Cyfra 21: 2.9, all in normal ranges. Subjectively and objectively he feels good, gain 6kg. Still taking Megamin by schema (12caps. +4grams of powder daily).

In addition, we present you a stroboscopic pictures taken before and after the treatment with Megamin:



1

14.3.2000.



2

13.1.2001.